

# Use of the Acellular Dermal Matrix in Revisionary Aesthetic Breast Surgery

G. Patrick Maxwell, MD; and Allen Gabriel, MD

**BACKGROUND:** Revisionary augmentation and revision of augmentation mastopexy are of considerable interest to plastic surgeons who perform breast surgery because of the procedures' complexity. In these cases, surgeons are faced with either thinned breast tissues resulting from large breast implants with tissue stretch or encapsulation caused by excessive scarring. To our knowledge, there are currently no large-series studies describing the use of acellular dermal matrices (ADM) in cosmetic breast surgery.

**OBJECTIVE:** The authors describe the use of the ADM in revisionary breast surgery to establish the aesthetic breast form.

**METHODS:** A retrospective chart review was conducted of 78 consecutive patients who underwent revisionary breast augmentation and augmentation mastopexies with ADM during a period of just over two years (October 2005 to January 2008). Data collected included patient characteristics, complications, outcomes, and reoperation rates.

**RESULTS:** Seventy-eight procedures were performed with ADM during the two-year period, with a minimum of 12 months of follow-up. There were two complications requiring reoperations for a hematoma and implant malposition, respectively. There were no Baker III or IV capsular contractures at one year postprocedure.

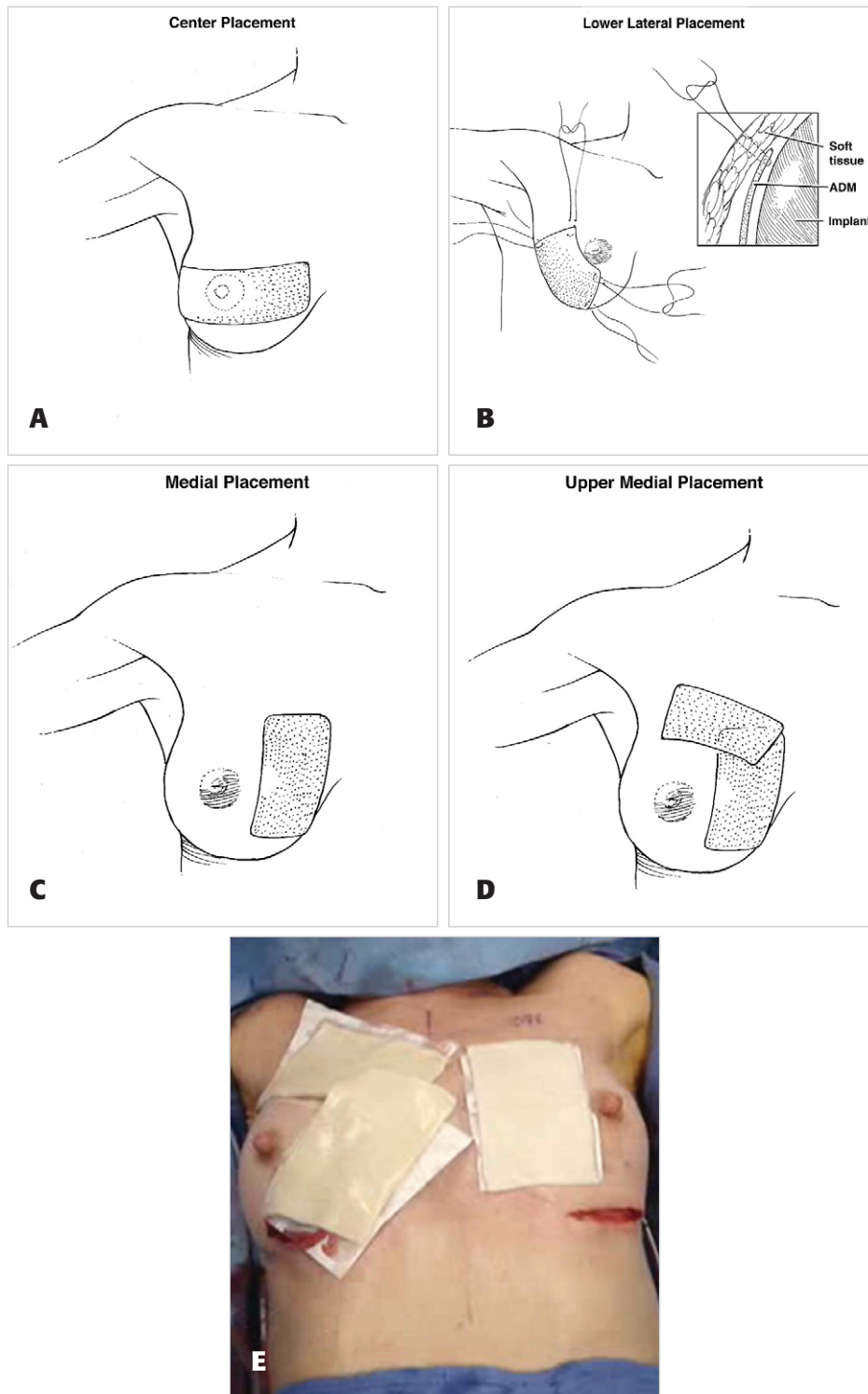
**CONCLUSIONS:** Revisionary augmentation and revision of augmentation mastopexy are commonly performed procedures and they have a significantly higher complication rate than primary procedures. This series shows that the ADM can be used both safely and effectively in revisionary cases, resulting in decreased rates of capsular contracture and implant cushioning/stabilization. (*Aesthet Surg J*; 29:485-493.)

In previous articles, we thoroughly discussed the controversy related to the safety of silicone gel-filled breast implants that led to the widespread use of submuscular saline implant placement in the 1990s.<sup>1-4</sup> Surgeons performing revisions of these surgeries confront thinned muscle tissues resulting from the placement of large implants in the subglandular or submuscular space. On the whole, revisionary breast surgery procedures are complex, challenging, and unpredictable because they often must address late complications of breast augmentation, one of which is capsular contracture (CC). CC has plagued plastic surgeons as the most common complication of aesthetic and reconstructive breast surgery for many years<sup>5,6</sup>; the majority of revisionary surgeries are performed because of CC.<sup>6,7</sup> Many etiologies have been proposed for this process and it is clear that prevention of it in primary cases includes sound techniques, such as precise and atraumatic bloodless dissection, appropriate triple-antibiotic breast pocket irrigation, and the minimization of contamination points during the procedure.<sup>8,9</sup>

Treatment of an established capsule can be challenging and multiple treatment techniques have been used. As with any pathophysiologic process, understanding the cellular disease progression can lead to innovative solutions. In this case, it is perspicuous that, at the cellular level, CC is most likely caused by any process that will produce increased inflammation, leading to the formation of deleterious cytokines. If this pathophysiological development is not controlled at an early stage, it can lead to increased thickness and contracture of the periprosthetic pocket. Consequently, in addition to all of the techniques for the treatment and prevention of CC described by many of our colleagues,<sup>1,5,8,10-16</sup> we believe that the acellular dermal matrix (ADM) is another modality in fighting the evolution of the capsule. ADM can counteract the inflammatory process adding greater availability of regenerative tissue to help control the interface of the implant pocket (Figure 1).

Over the course of many years, options for revision and improvement have included replacing saline implants with silicone gel-filled implants, using capsular flaps to gain additional stability and coverage, or performing a site change operation, none of which can achieve complete resolution of some of the implant issues.<sup>1,4,17</sup>

Dr. Maxwell is Clinical Professor of Surgery and Dr. Gabriel is Director of Research in the Department of Plastic Surgery, Loma Linda University Medical Center, Loma Linda, CA.



**Figure 1.** Placement of the acellular dermal matrix is shown in the center (A), lower lateral (B), medial (C), and upper medial (D) areas. In the intraoperative photo (E), medial placement can be seen on the patient's left breast and upper medial placement is shown on the right breast.

Capsular flaps are available, but some patients with implant malposition have extremely thin tissues and these flaps only allow for subtle improvements.

ADM products have been popularized lately in both breast and abdominal wall reconstructions.<sup>18-28</sup> In cases of reconstruction, they have been used to either replace tissue, extend existing tissue, or act as a supplement. In

aesthetic cases, they are used to correct implant rippling and displacement, including symmastia.<sup>29-31</sup> To our knowledge, no evaluations have been performed for the use of the ADM in CC. The authors believe that, with regard to CC, we are dealing with a phenomenon very similar to lamellar scarring in the eyelids. We hypothesized that by releasing or removing scar and replacing

**Table 1.** Products studied

Product name	Manufacturer	Origin	Method of preservation	Year introduced	Time to hydrate	Shelf life	Refrigeration required?
Alloderm	LifeCell	Human dermal collagen	Lyophilized, patented freeze-drying process prevents damaging ice crystals from forming	1994	20–40 minutes with saline solution step bath with agitation	2 years	Yes
Neoform	Regeneration Technologies Tutogen Medical, for Mentor	Human dermal collagen	Solvent dehydrated; gamma-irradiated	2007	A few minutes with room temperature saline	5 years	No
DermaMatrix	Processed by MTF for Synthes CMF	Donated acellular human dermis	Aseptic processing method, lyophilized	2005	None	18 months or 3 years	No
FlexHD	Processed by the MTF for Ethicon	Donated acellular human dermis	Aseptic processing method, lyophilized	2007	None	18 months or 3 years	No
SurgiMend	TEI Biosciences	Fetal bovine dermal collagen	Terminally stabilized	2007	60 seconds with room temperature saline	3 years	No
Strattice	LifeCell	Porcine dermal collagen	Patented freeze-drying process that prevents damaging ice crystals from forming	2008	Minimum of 2 minutes in sterile saline	?	No

MTF, Musculoskeletal Transplant Foundation.

the missing or scarred tissue with regenerative tissue, we would see a smaller incidence of CC in our patients.

## METHODS

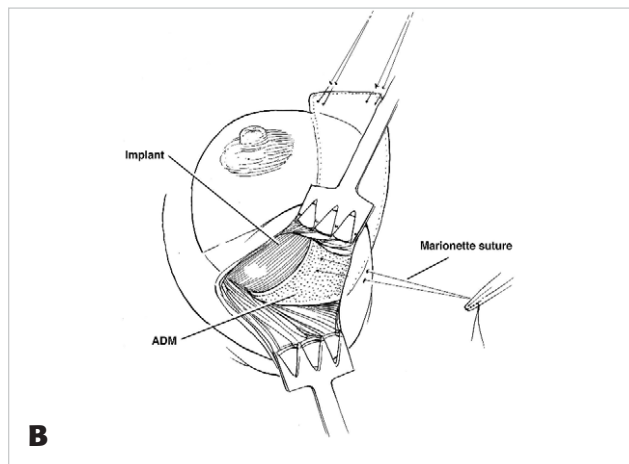
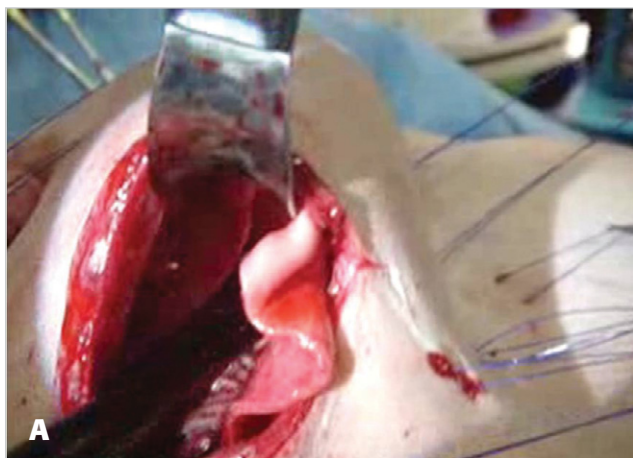
A retrospective chart review was conducted of 78 consecutive patients who underwent revisionary breast augmentation/mastopexies with ADM during a period of slightly more than two years (October 2005 to January 2008). Patients undergoing surgery for implant rupture, implant malposition, or other reasons without ADM were not included. Only charts with complete operative reports or those in which the use of the ADM could be definitively ascertained were included in the study. Data were collected regarding the original augmentation date, the original implant location (subpectoral or subglandular), type of incision used, volume of the implant used, revision date, type of implant used for revision, incision used in revision, length of follow-up, and any complications that ensued.

All patients received perioperative antibiotics, with the majority receiving first-generation cephalosporin. All surgical pockets were irrigated with triple antibi-

otic solutions and the implants were bathed in the same solution before insertion into the new pocket. The implants were handled as little as necessary to minimize possible contamination.

For patients whose original implants were subglandular, a site change to a subpectoral plane was performed, with lower pole coverage with ADM. For patients whose original implants were placed subpectorally, a neopectoral pocket was dissected, with the addition of an ADM. For patients who did have adequate breast tissue, a subfascial pocket with an ADM sling was fashioned. In the subpectoral procedures, the pectoralis major muscle was released entirely across its inferior origin and the subpectoral pocket was released as far medially as necessary to achieve the desired pocket shape and medial breast border. Three to five half-mattress stabilizing marionette sutures were placed between the skin and the ADM to stabilize the tissue and hold it in the desired location (Figure 2).

Six different types of ADM products were used for this series (Table 1). The majority of patients received Alloderm or Strattice (LifeCell, Branchburg, NJ), FlexHD



**Figure 2.** The acellular dermal matrix is secured with marionette sutures. This process is depicted in both the intraoperative photo (A) and the illustration (B).

**Table 2.** Time interval for conversion

	Total	Previous implant	
		Subpectoral	Subglandular
No. of patients	78	56	22
Time to revision, months	93	95	90
Follow-up, months	12	11.9	12.1

**Table 3.** Types of implants used as replacements

	Total	Silicone gel-filled	Cohesive gel
Total	78	45	33
Textured	73	40	33
Smooth	5	5	—

**Table 4.** Complications

Complication	No. of patients
Hematoma	1
Seroma	2
Implant malposition	1
Implant rupture	0
Infection	0
Total	4

or DermaMatrix (MTF, Edison, NJ) or SurgiMend (TEI Biosciences, Boston, MA). The majority of the products were listed as thick on the product label (if a product description was available). All dermal products were soaked in triple antibiotic solution before placement.

## RESULTS

A total of 78 patients who met all of the criteria for this review were identified. Fifty-six patients had their original implants in the subpectoral position and 22 had them in the

subglandular position. The average time from initial operation to revision was seven years, nine months (originally subpectoral: seven years, 11 months; originally subglandular: seven years, six months). The average time for follow-up after pocket conversion was at least 12 months for all patients (originally subpectoral: 11.9 months; originally subglandular, 12.1 months; [Table 2](#)). Eleven patients (20%) with previous subpectoral implants were noted to have implant rupture at the time of revision and the previous subglandular implants were ruptured in five patients (23%).

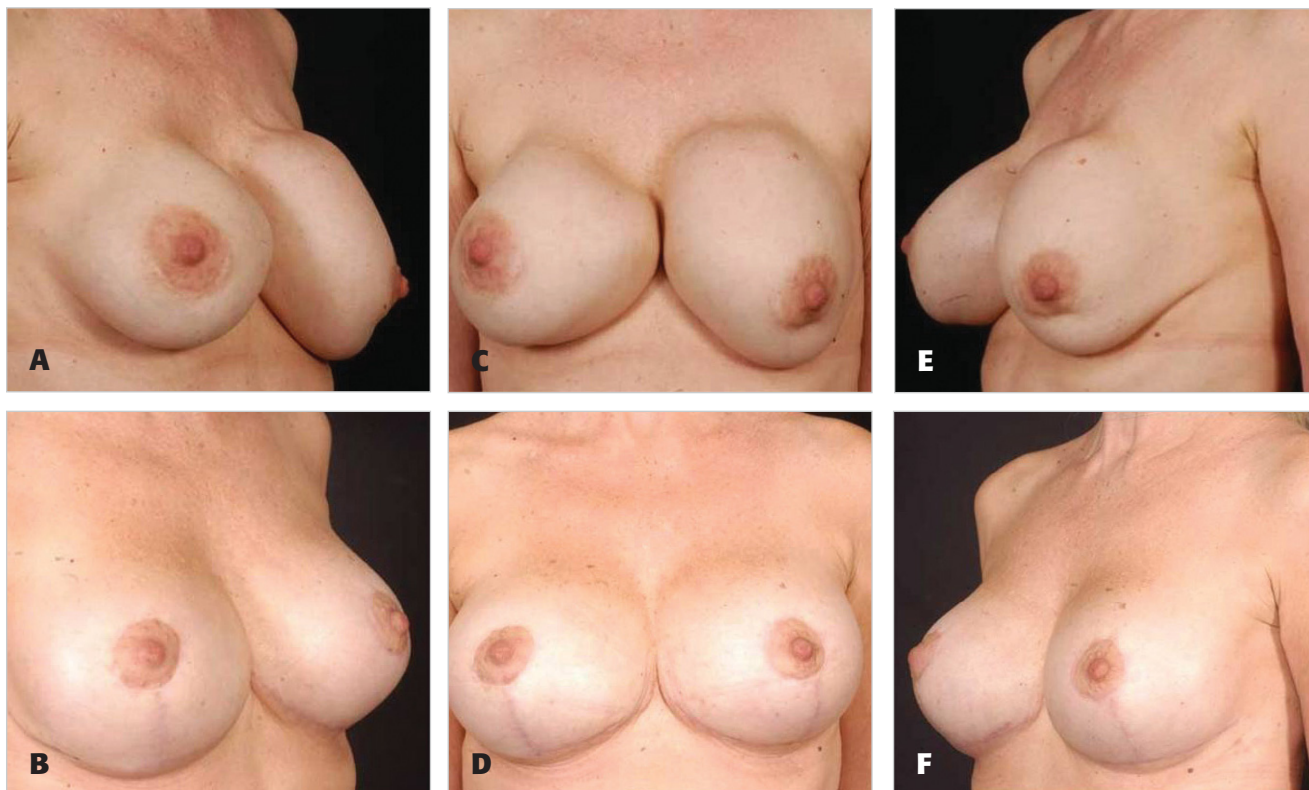
Among the 56 patients with previously subpectoral implants, 11 patients were found to have ruptured implants. Five patients had silicone gel-filled implants, three patients had double-lumen implants in which only the saline component was found to be ruptured, and three patients had a double-lumen implant in which both components showed evidence of rupture. Among the 22 patients with original subglandular implants, five patients were found to have ruptured implants. All five patients had silicone gel-filled implants. None of the patients with ruptured implants had any preoperative complaints or physical findings suggestive of implant rupture.

Forty-five patients (60%) had replacement with silicone gel-filled implants (five smooth, 40 textured) and 33 (40%) had replacement with form-stable, highly cohesive gel implants ([Table 3](#)). Complications included two patients (2.5%) requiring reoperation, one for a hematoma and the other for an implant malposition ([Table 4](#)).

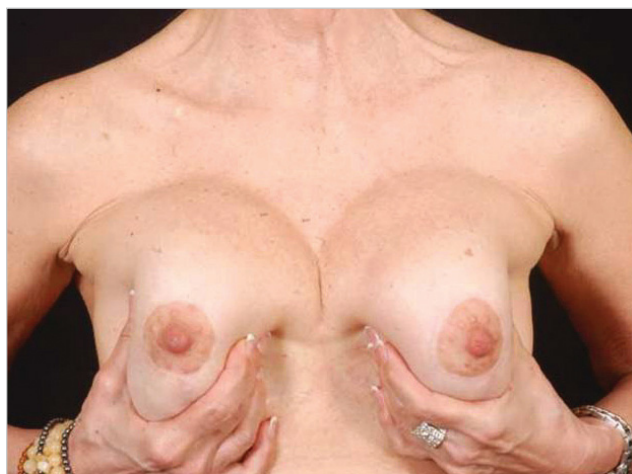Of the 54 patients whose implants were initially subpectoral, 23 patients (43%) had silicone gel-filled implants, 15 patients (28%) had double-lumen implants, and 16 patients (30%) had saline implants. Of the 31 patients whose implants were originally subglandular, 20 patients (65%) had silicone gel-filled implants, three patients (10%) had double-lumen implants, and eight patients (26%) had saline implants.

Presenting clinical signs are listed in [Table 5](#) and the types of operations performed are listed in [Table 6](#). As expected, the majority of complaints were related





**Figure 3.** A, C, E, Preoperative views of a 42-year-old woman who had undergone multiple previous augmentation procedures. B, D, F, Sixteen months after revision augmentation mastopexy with circumvertical purse-string approach and an acellular dermal matrix. Her large implants were exchanged for higher-profile, lower-volume textured implants.



**Figure 4.** The patient in Figure 3 is shown one year postoperatively.

to implant hardening. Of 78 patients, 77 (98.5%) were assessed as having soft implants with a Baker I level of CC at final follow-up; one patient (1.5%) had a Baker II CC. No patients had a Baker III or Baker IV classification postoperatively (Tables 7, 8, and 9). Between January 2008 and January 2009, an additional 41 cases have been performed for CC, increasing the total number of patients in the series to 119. Because we established a minimum follow-up period of one year, we have not included them in this series. However, it is worth noting that all of these newer

patients have maintained a Baker I classification at a mean follow-up of 6.2 months. Results from the study are shown in Figures 3 to 6.

## DISCUSSION

The successful use of ADM products has been reported in a wide range of clinical settings, including abdominal wall repair, hernia repair, facial and eyelid surgery, cleft palate repair, soft tissue augmentation, tendon repair, ulcer repair, vaginal sling repair, and breast reconstruction.<sup>18-28</sup> Immediate breast reconstruction using tissue expanders or implants has become one of the most commonly used surgical techniques, which has made visible rippling and contour deformity a more frequently encountered problem.<sup>31</sup> Therefore, the applications of ADM to breast reconstruction have been of particular interest to plastic surgeons. The recent addition of allogenic tissue supplements avoids the problems of autologous tissue coverage and provides camouflage, thereby decreasing rippling and increasing soft tissue padding.<sup>32</sup> This rising demand, coupled with good outcomes in breast reconstruction, has spurred tremendous interest about ADM use in aesthetic breast patients, particularly in the management of CC.

In the past, revisionary surgeries for CC were generally performed with a total capsulectomy, removal of the implant from the subglandular plane, and the placement of a new implant in the subpectoral position.<sup>1,4,16</sup> This is a fairly simple procedure involving a change in implant placement from over the muscle to under the muscle. More recently, it

**Table 5.** Clinical signs at presentation

Clinical signs	No. of patients
Capsular contracture	56
Implant exposure	2
Rippling	7
Implant malposition	5
Bottoming out	4
Symmastia	4
Total	78

**Table 6.** Augmentation versus augmentation mastopexy

	No. of patients
Augmentation	49
Augmentation/mastopexy	29
Total	78

**Table 7.** Preoperative and postoperative Baker classification of patients with originally subpectoral implants

Baker classification	Percent of patients	
	Preoperative	Postoperative
I	5.4	98.5
II	21.1	1.5
III	67.9	0
IV	5.6	0

**Table 8.** Preoperative and postoperative Baker classification of patients with originally subglandular implants

Baker classification	Percent of patients	
	Preoperative	Postoperative
I	9.1	97.4
II	18.2	2.6
III	54.5	0
IV	18.2	0

**Table 9.** Preoperative and postoperative Baker classification in all patients

Baker classification	Percent of patients	
	Preoperative	Postoperative
I	6.4	97.4
II	20.5	2.6
III	64.1	0
IV	9.0	0

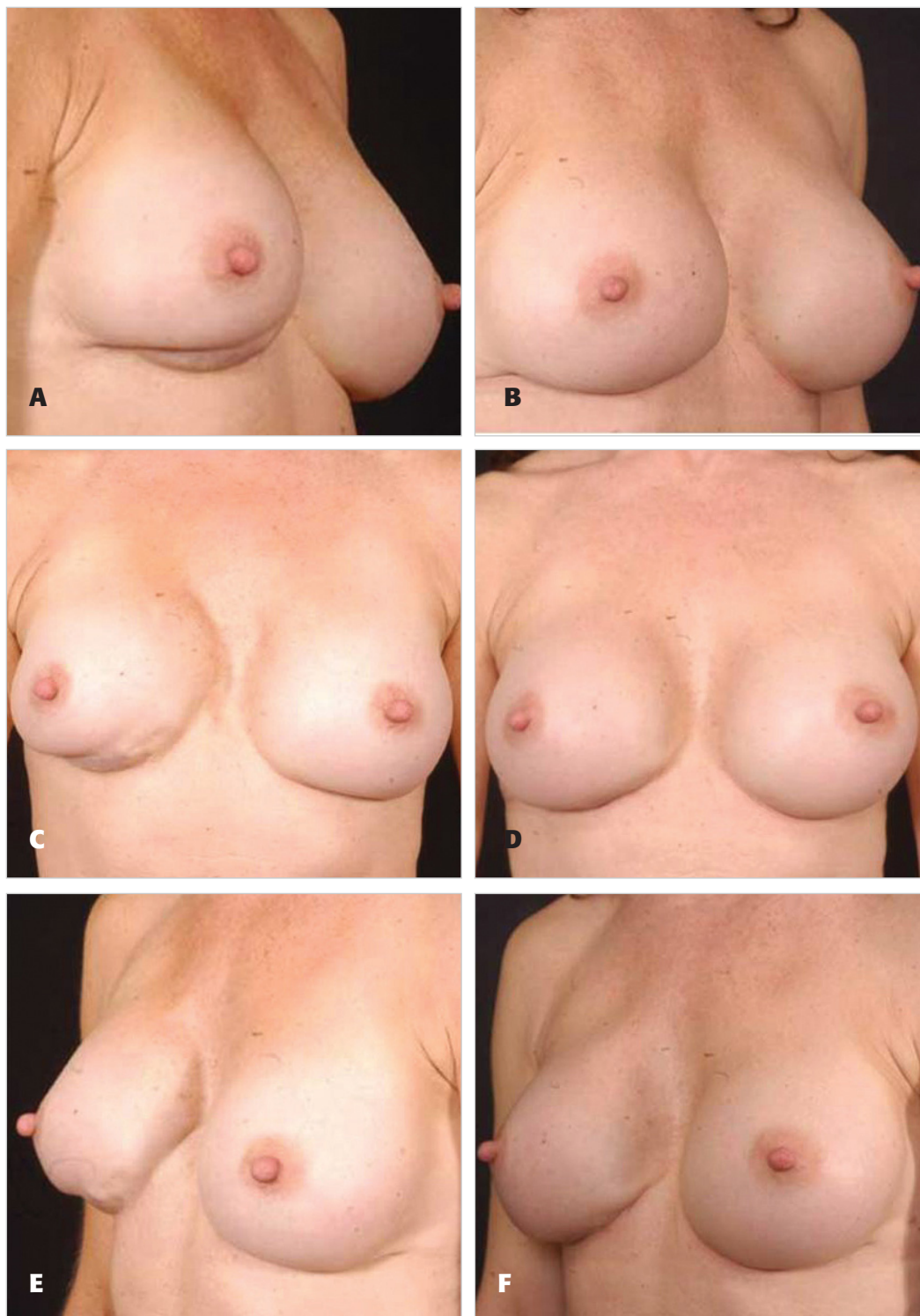
has become necessary to perform revisionary surgery on volume-depleted breasts as a result of large implants that were placed under the muscle or severe scarring in the breasts. We remain plagued with a paucity of tissue, leading to the use of allogenic materials such as ADM.

Our experience with 78 patients—all of whom uniformly had their implant-related complications successfully corrected by a site change and the use of an ADM—provides a number of important conclusions. First, the use of ADM enhanced soft tissue thickness or cushioning (Figure 5), decreasing and eliminating the visibility of implants. Second, the use of these products increased our ability to successfully manage implant displacements and their recurrence. Third, lower pole thickness was enhanced in patients with dual plane or neopectoral pocket conversions, especially in those undergoing concurrent mastopexies, interposing regenerative tissue between skin closure and implant (lamellar interpositioning) (Figure 6). Lastly, it is of interest that 56 patients with Baker grade III and IV CC had their CC treated successfully.

The addition of the ADM to the management of breast augmentation intricacies gives us an exciting and, according to our data, reliable new surgical option. It is evident that by replacing the missing tissue at the implant interface, we are able to create an environment that is conducive to healing without excessive scarring (Figure 1). Unpublished results from our animal studies show decreased inflammation within the implanted pocket at different time points with the addition of ADM.<sup>33</sup> Just as with any process that leads to excessive scarring, the key is to control the inflammatory phase and allow the healing tissue to transition quickly and smoothly to the next (proliferative) phase. It is also important to keep in mind that the true etiology of CC remains multifactorial and, by controlling all of the factors, we are able to see the future in prevention of this complicated and prolonged issue.

ADM is not a miracle product that can eliminate CC, but it serves as an adjunct to the already well-described principles in the management of CC, such as aseptic techniques with appropriate antibacterial pocket irrigations, postoperative drains, and the placement of textured implants.<sup>1,3,4,8,9,11,15,34</sup> We postulate that in order to have a successful outcome with an ADM, the creation of a new pocket (raw surface) is essential to augment the interface (Figures 2 and 3). We do not believe that partial capsulectomy or capsulotomies in conjunction with placement of an ADM are as effective as lining the ADM in a newly vascularized pocket, followed by placement of the implant (Figure 7).

With our extensive use of all types of ADM, we have found no differences in terms of complications, as noted by our data. ADM products have their limitations and differences in terms of revascularization and cellular ingrowth and the acceptance between different thicknesses and sterility, but we noted no additional drainage output and no infections related to the sterility of certain products. As previously noted, the majority of products were listed as thick on the product label (if available). It should be noted, however,



**Figure 5.** **A, C, E,** Preoperative views of a 40-year-old woman who had undergone multiple previous augmentation procedures. **B, D, F,** Fourteen months after mastopexy with an inframammary fold approach and acellular dermal matrix. Her implants were exchanged for textured silicone gel-filled implants.

that the different materials have different biomechanical properties, a discussion of which is beyond the scope of this article.

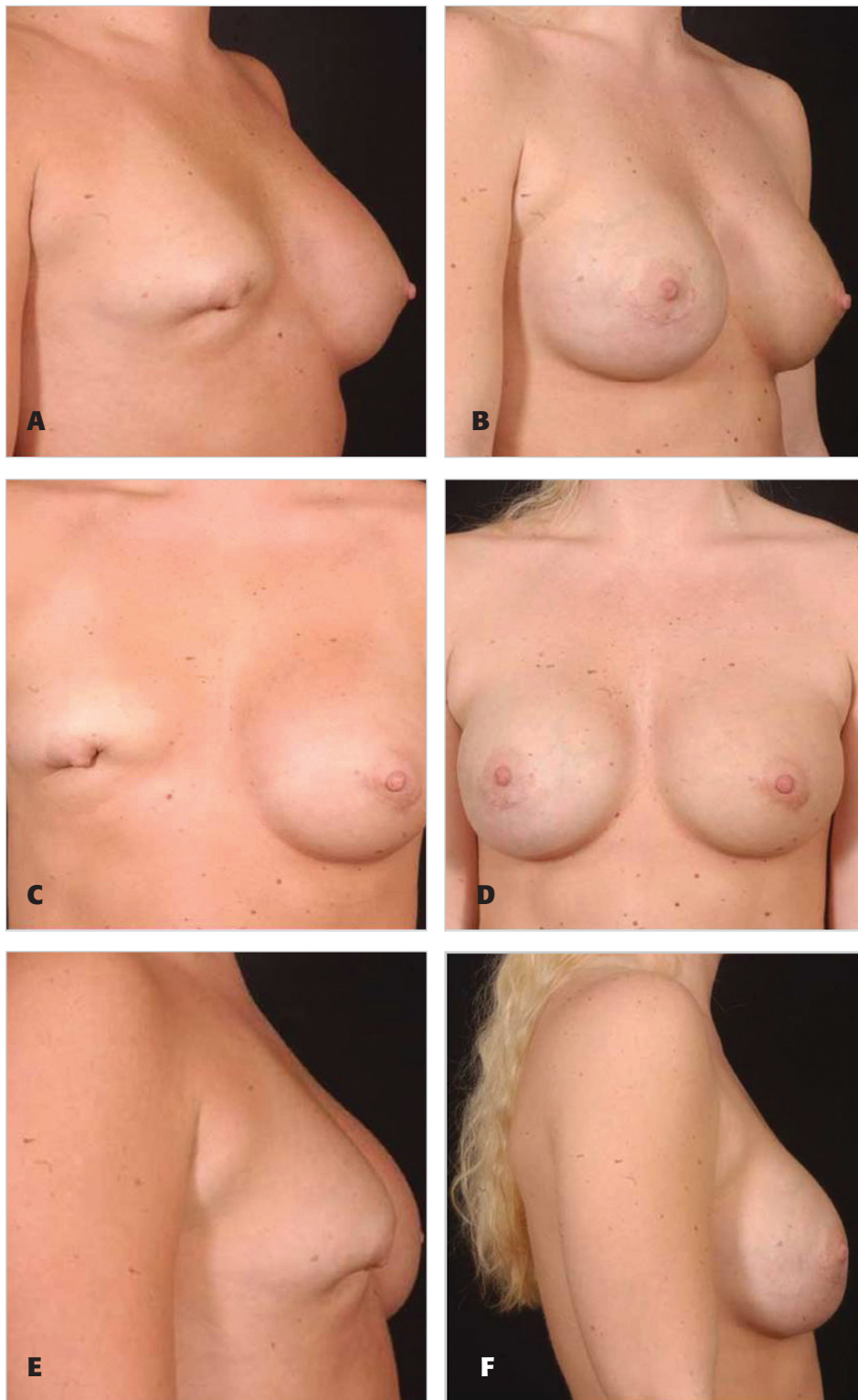
One obstacle that we will continue to face in aesthetic surgery is the cost-benefit ratio of these materials, as they are expensive. Further evaluation is needed to assess the

actual impact of these costs and their documented outcome improvements in our specialty.

## CONCLUSIONS

ADM products show promise for applications in revisionary breast surgery and specifically for the treatment of





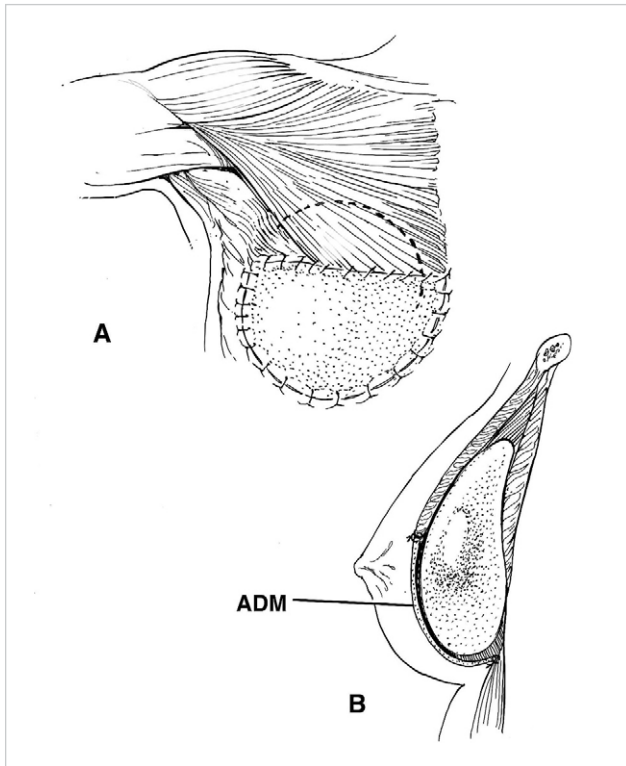
**Figure 6.** **A, C, E,** Preoperative views of a 35-year-old woman with previous subpectoral augmentation with saline implants, with extrusion and lamellar scarring. **B, D, F,** Fourteen months after mastopexy with acellular dermal matrix. Her implants were exchanged for textured silicone gel-filled implants.

complications of breast augmentation. This report describes different uses of the ADM that allow for the correction of established CC, malposition, and other implant-related issues after previous subglandular or subpectoral breast augmentation. ▀

## DISCLOSURES

*Dr. Maxwell is a paid consultant to Allergan. Dr. Gabriel is on the speaker's bureau of Lifecell.*





**Figure 7.** Interposing regenerative tissue between skin closure and implant (lamellar interpositioning).

## REFERENCES

1. Maxwell GP, Gabriel A. The neopeitoral pocket in revisionary breast surgery. *Aesthet Surg J* 2008;28:463–467.
2. Maxwell GP, Gabriel A. Possible future development of implants and breast augmentation. *Clin Plast Surg* 2009;36:167–172.
3. Maxwell GP, Gabriel A. The evolution of breast implants. *Clin Plast Surg* 2009;36:1–13.
4. Maxwell GP, Gabriel A. Efficacy of the neopeitoral pocket in revisionary breast surgery. *Aesthet Surg J* 2009;29:379–385.
5. Spear SL, Carter ME, Ganz JC. The correction of capsular contracture by conversion to “dual-plane” positioning: technique and outcomes. *Plast Reconstr Surg* 2006;118(7 suppl):103S–113S.
6. Spear SL, Murphy DK, Slicton A, Walker PS, Inamed Silicone Breast Implant U.S. Study Group. Inamed silicone breast implant core study results at 6 years. *Plast Reconstr Surg* 2007;120(7 suppl 1):8S–16S.
7. Cunningham B. The Mentor Core Study on Silicone MemoryGel Breast Implants. *Plast Reconstr Surg* 2007;120(7 suppl 1):19S–29S.
8. Adams Jr WP, Rios JL, Smith SJ. Enhancing patient outcomes in aesthetic and reconstructive breast surgery using triple antibiotic breast irrigation: six-year prospective clinical study. *Plast Reconstr Surg* 2006;117:30–36.
9. Adams Jr WP. Capsular contracture: what is it? What causes it? How can it be prevented and managed? *Clin Plast Surg* 2009;36:119–126.
10. Gancedo M, Ruiz-Corro L, Salazar-Montes A, Rincón AR, Armendariz-Borunda J. Pirfenidone prevents capsular contracture after mammary implantation. *Aesthetic Plast Surg* 2008;32:32–40.
11. Ma SL, Gao WC. Capsular contracture in breast augmentation with textured versus smooth mammary implants: a systematic review [in Chinese]. *Zhonghua Zheng Xing Wai Ke Za Zhi* 2008;24:71–74.
12. Scuderi N, Mazzocchi M, Rubino C. Effects of zafirlukast on capsular contracture: controlled study measuring the mammary compliance. *Int J Immunopathol Pharmacol* 2007;20:577–584.
13. Weintraub JL, Kahn DM. The timing of implant exchange in the development of capsular contracture after breast reconstruction. *Eplasty* 2008;8:e31.
14. Wiener TC. Relationship of incision choice to capsular contracture. *Aesthetic Plast Surg* 2008;32:303–306.
15. Wong CH, Samuel M, Tan BK, Song C. Capsular contracture in subglandular breast augmentation with textured versus smooth breast implants: a systematic review. *Plast Reconstr Surg* 2006;118:1224–1236.
16. Zimman OA, Toblli J, Stella I, Ferder M, Ferder L, Inserra F. The effects of angiotensin-converting enzyme inhibitors on the fibrous envelope around mammary implants. *Plast Reconstr Surg* 2007;120:2025–2033.
17. Maxwell GP, Tebbetts JB, Hester TR. Site change in breast surgery. Presented at the American Association of Plastic Surgeons annual meeting, St. Louis, MO, May 1994.
18. Bindingave V, Gaon M, Ota KS, Kulber DA, Lee DJ. Use of acellular cadaveric dermis and tissue expansion in postmastectomy breast reconstruction. *J Plast Reconstr Aesthet Surg* 2007;60:1214–1218.
19. Breuing KH, Warren SM. Immediate bilateral breast reconstruction with implants and inferolateral AlloDerm slings. *Ann Plast Surg* 2005;55:232–239.
20. Breuing KH, Colwell AS. Inferolateral AlloDerm hammock for implant coverage in breast reconstruction. *Ann Plast Surg* 2007;59:250–255.
21. Cothren CC, Gallego K, Anderson ED, Schmidt D. Chest wall reconstruction with acellular dermal matrix (AlloDerm) and a latissimus muscle flap. *Plast Reconstr Surg* 2004;114:1015–1017.
22. Garramone CE, Lam B. Use of AlloDerm in primary nipple reconstruction to improve long-term nipple projection. *Plast Reconstr Surg* 2007;119:1663–1668.
23. Glasberg SB, D’Amico RA. Use of regenerative human acellular tissue (AlloDerm) to reconstruct the abdominal wall following pedicle TRAM flap breast reconstruction surgery. *Plast Reconstr Surg* 2006;118:8–15.
24. Kim H, Bruen K, Vargo D. Acellular dermal matrix in the management of high-risk abdominal wall defects. *Am J Surg* 2006;192:705–709.
25. Nahabedian MY. Secondary nipple reconstruction using local flaps and AlloDerm. *Plast Reconstr Surg* 2005;115:2056–2061.
26. Patton Jr JH, Berry S, Kralovich KA. Use of human acellular dermal matrix in complex and contaminated abdominal wall reconstructions. *Am J Surg* 2007;193:360–363.
27. Salzberg CA. Nonexpansive immediate breast reconstruction using human acellular tissue matrix graft (AlloDerm). *Ann Plast Surg* 2006;57:1–5.
28. Spear SL, Parikh PM, Reisin E, Menon NG. Acellular dermis-assisted breast reconstruction. *Aesthetic Plast Surg* 2008;32:418–425.
29. Duncan DI. Correction of implant rippling using allograft dermis. *Aesthet Surg J* 2001;21:81–84.
30. Baxter RA. Intracapsular allogenic dermal grafts for breast implant-related problems. *Plast Reconstr Surg* 2003;112:1692–1696.
31. Colwell AS, Breuing KH. Improving shape and symmetry in mastopexy with autologous or cadaveric dermal slings. *Ann Plast Surg* 2008;61:138–142.
32. Gamboa-Bobadilla GM. Implant breast reconstruction using acellular dermal matrix. *Ann Plast Surg* 2006;56:22–25.
33. Maxwell GP, Gabriel A, Perry LC. Role of acellular dermal matrix in inflammation (unpublished) 2009.
34. Schreml S, Heine N, Eisenmann-Klein M, Prantl L. Bacterial colonization is of major relevance for high-grade capsular contracture after augmentation mammoplasty. *Ann Plast Surg* 2007;59:126–130.

Accepted for publication February 16, 2009.

Presented at the 58th Annual Meeting of California Society of Plastic Surgeons, Dana Point, CA, June 2008, and the 24th Annual Meeting of Breast Surgery Symposium, Atlanta, GA, January 2008.

Reprint requests: Patrick Maxwell, MD, Department of Plastic Surgery, Loma Linda University Medical Center, 11234 Anderson St., Loma Linda, CA 92354. E-mail: [gabrielallen@yahoo.com](mailto:gabrielallen@yahoo.com).

Copyright © 2009 by The American Society for Aesthetic Plastic Surgery, Inc. 1090-820X/\$36.00

doi:10.1016/j.asj.2009.09.007